

Rare site of presentation of a rare manifestation of graves' disease

Sreenath Ravindranath¹, Arjun Baidya², Nilanjan Sengupta³, Pranab Kumar Sahana⁴, Soumik Goswami⁵, Arindam Ray¹

From ¹Senior Resident, ²Assistant Professor, ³Professor and Head, ⁴Associate Professor, ⁵RMO and Clinical Tutor, Department of Endocrinology, NRS MCH, Kolkata, West Bengal, India

Correspondence to: Dr. Sreenath Ravindranath, Department of Endocrinology Senior Resident, NRS MCH, Kolkata - 700 010, West Bengal, India. E-mail: dr.sreenathr@gmail.com

Received - 27 October 2018

Initial Review - 13 November 2018

Accepted - 16 December 2018

ABSTRACT

Infiltrative dermopathy is an uncommon manifestation of Graves' disease frequently involving the lower extremities. The pretibial area is most commonly involved. Rarely the fingers, hands, elbows, arms, or face are affected. Skin thickening is the characteristic abnormality. Localized myxedema is an autoimmune manifestation of Graves' disease. Here, we report the case of a 45-year-old who presented with thyroid-associated orbitopathy and localized myxoedema over both the shoulders. In a patient who has long-standing hyperthyroidism, the diagnosis of infiltrative dermopathy is usually confirmed by the location, non-pitting nature, and distinct borders of the lesions. As most of these lesions are asymptomatic, no specific therapy is required.

Key words: Graves' disease, Infiltrative dermopathy, Localized myxedema

Infiltrative dermopathy is an uncommon manifestation of Graves' disease frequently involving the lower extremities. The natural course of this condition is not well-defined. It is seen usually after 2–3 years of onset of thyrotoxicosis. The pretibial area is the most commonly involved (99.4%) region [1,2]. Rarely the fingers, hands, elbows, arms, or face are affected. We report a case who presented with thyroid-associated orbitopathy and localized myxoedema over both the shoulders. The literature on Graves' dermopathy indicates that this form of dermopathy is unusual [1,3,4].

CASE REPORT

A 45-year-old male presented to our outdoor department with complaints of palpitations, tremor, profuse sweating, and hyperdefecation. He gave a history of taking carbimazole 30 mg once daily and propranolol 40 mg once daily.

On physical examination, pulse rate was 104/min and regular, blood pressure was 116/74 mm of Hg. The patient had exophthalmos and the thyroid gland was diffusely enlarged with a firm texture, but no nodules were present (Fig. 1). The pretibial portion and feet were normal. Localized non-tender swelling was noted over both his shoulders (Fig. 2). On further enquiry, he revealed the history of carrying fish baskets tied to a pole over his shoulders.

The clinical features were suggestive of thyrotoxicosis and thyroid-associated orbitopathy. A skin biopsy was done from the shoulder lesion which showed deposits of eosinophilic hyaline material and mild perivascular inflammatory cell infiltration

in the dermis suggestive of myxedema (Fig. 3). His clinical activity score (CAS) was 4/7, free T4 was 2.9 ng/dl, and thyroid stimulating hormone (TSH) was 0.013 micro IU/L.

Since the patient was having active Graves' orbitopathy, he was started on weekly methylprednisolone therapy and was followed up for 12 weeks. During his follow-up visit after 1 month, his orbitopathy (CAS=1/7) and thyroid function improved (Free T4=1.5 ng/dl).

DISCUSSION

The patient presented in our case report had Graves' ophthalmopathy and dermopathy. Moreover, he had the unusual presentation of localized myxedema involving both suprascapular areas. Graves' disease is characterized by thyrotoxicosis, diffuse goiter, infiltrative orbitopathy and occasionally, and infiltrative dermopathy [5]. The least common manifestation of Graves' disease is infiltrative dermopathy. It occurs in up to 4–5% of patients with Graves' disease [1,2]. Skin thickening is the characteristic abnormality and is usually limited to the pretibial area (99.4%). Hence, it has been called pretibial myxedema. Localized myxedema is a more appropriate term as it involves other areas also occasionally [1,6].

Localized myxedema is an autoimmune manifestation of Graves' disease, and the usual pretibial localization relates to mechanical factors and dependent position [7]. Rarely the fingers, hands, elbows, arms, or face are affected. The TSH receptor is the antigen for T-cell reaction, and TSH receptor antibodies are important in the pathogenesis of Graves' dermopathy, similar

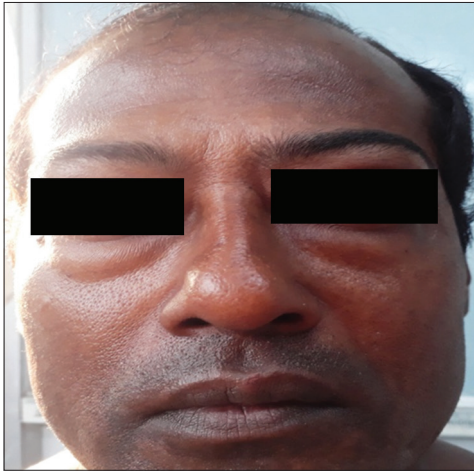

Figure 1: The patient showing exophthalmos

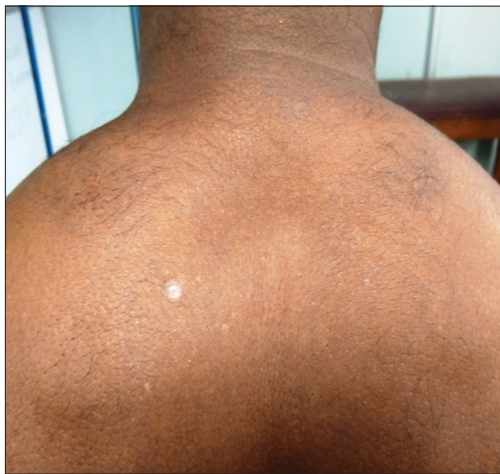

Figure 2: Localized non-tender swelling over both the shoulders

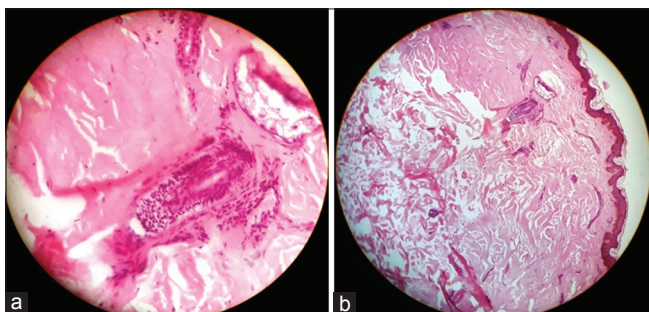


Figure 3: (a and b) Histopathology showing deposits of eosinophilic hyaline material and mild perivascular inflammatory cell infiltration in the dermis

to that of Graves' orbitopathy. This also explains the occasional worsening of dermatopathy after trauma, surgery, and radioiodine therapy for hyperthyroidism [5,7,8].

Clinical features of infiltrative dermatopathy are non-pitting scaly thickening and induration of the skin, papules, nodules, pigmentation, plaque, and rarely elephantiasis form [1,6]. Hyaluronic acid and chondroitin sulfate content in the dermis are increased leading to compression of the dermal lymphatics and non-pitting edema [1,5,7]. Differential diagnoses of infiltrative dermatopathy are chronic lymphatic and venous obstruction

of the lower extremities, chronic dermatitis, and cutaneous mucinosis. To establish the correct diagnosis, a skin biopsy may be necessary [9].

In a patient who has longstanding hyperthyroidism, the diagnosis of infiltrative dermatopathy is usually confirmed by the location, non-pitting nature, and distinct borders of the lesions. In this case, both the location and nature of the lesion were atypical, and biopsy was necessary to establish the correct diagnosis and differentiate it from chronic dermatitis and cutaneous mucinosis. The histopathology of the skin showed deposits of eosinophilic hyaline material in the dermis with mild perivascular inflammatory cell infiltrate which were typical and diagnostic (Fig. 3). As most of these lesions are asymptomatic, no specific therapy is required. For symptomatic cases, topical corticosteroid therapy under occlusive or compressive dressings is recommended. Up to 50% of lesions go into complete or partial remission over time.

CONCLUSION

Graves' dermatopathy is a rare manifestation of the Graves' disease. A skin biopsy is confirmatory of the condition. Since most of the times the lesions are asymptomatic, no specific therapy is required.

ACKNOWLEDGEMENT

The authors would like to thank patient.

REFERENCES

1. Fatourechi V, Pajouhi M, Fransway AF. Dermopathy of graves' disease. *Medicine* 1994;73:1.
2. Terry F, Davies P, Larsen PR. Thyrotoxicosis. In: Larsen PR, Kronenberg H, Melmed S, editors. *Williams Textbook of Endocrinology*. 10th ed. Philadelphia, PA: WB Saunders; 2003. p. 379-401.
3. Fatourechi V, Ahmed DD, Schwartz KM. Thyroidacropathy: Report of 40 patients treated at a single institution in a 26-year period. *J Clin Endocrinol Metab* 2002;87:5435-41.
4. Schwarts KM, Fatourechi V, Ahmad DD, Pond GR. Dermatology of graves' disease (pretibial myxedema): Long-term outcome. *J Clin Endocrinol Metab* 2002;87:438-46.
5. Anderson CK, Miller OF 3rd. Triad of exophthalmos, pretibial myxedema, and acropachy in a patient with graves' disease. *J Am Acad Dermatol* 2003;48:970-2.
6. Chiovato L, Barbesino G, Pinchera A. *Graves Disease Endocrinology*. 4th ed. Philadelphia, PA: WB Saunders; 2001.
7. Fatourechi V. Pretibial myxedema: Pathophysiology and treatment options. *Am J Clin Dermatol* 2005;6:295-309.
8. Harvey RD, Metcalfe RA, Morteo C, Furmaniak W, Weetman AP, Bevan JS, *et al.* Acute pre-tibial myxoedema following radioiodine therapy for thyrotoxic graves' disease. *Clin Endocrinol (Oxf)* 1995;42:657-60.
9. Davies TF. *Infiltrative Dermopathy (Pretibial Myxedema) in Thyroid Disease*. Version 13. 3. Uptodate; 2005.

Funding: None; Conflict of Interest: None Stated.

How to cite this article: Ravindranath S, Baidya A, Sengupta N, Sahana PK, Goswami S, Ray A. Rare site of presentation of a rare manifestation of graves' disease. *Indian J Case Reports*. 2018; December 29 [Epub ahead of print].