

Down syndrome with ambiguous genitalia: A rare association

Rahul Valsaraj¹, Soumik Goswami², Arindam Ray¹, Nilanjan Sengupta³, Pranab Kumar Sahana⁴, Arjun Baidya⁵

¹Post Doctoral Trainee, ²RMO Cum Clinical Tutor, ³Professor and Head, ⁴Associate Professor, ⁵Assistant Professor, Department of Endocrinology, Nilratan Sircar Medical College, Kolkata, West Bengal, India

Correspondence to: Dr. Rahul Valsaraj, Department of Endocrinology, Nilratan Sircar Medical College, 138 AJC Bose Road, Sealdah, Raja Bazaar, Kolkata - 700 014, West Bengal, India. E-mail: rahulvals@gmail.com

Received - 23 September 2018

Initial Review - 08 October 2018

Accepted - 16 November 2018

ABSTRACT

Down syndrome (DS) is one of the most common chromosomal disorders. Although genitourinary anomalies, such as a cryptorchidism, micropenis, posterior urethral valves, and hypospadias, have been recognized as complications, the association of ambiguous genitalia with DS has been rarely reported. We report the case of a 1-year-old baby; assigned male sex at birth who was the first child born of a non-consanguineous marriage, by vaginal delivery at term with a birth weight of 2.2 kg. The baby had clinical features suggestive of DS with a micropenis, penoscrotal hypospadias, and incompletely fused labial-scrotal folds with palpable gonads. The external masculinization score was 3/12. The child was reared as a male and hormonal investigations were suggestive of androgen insensitivity. Karyotype was 47, XY, +21.

Keywords: *Ambiguous genitalia, Androgen insensitivity, Down syndrome*

Down syndrome (DS) is one of the most common genetic disorders which can be attributable to multiple maternal and environmental risk factors. Although isolated urogenital complications such as cryptorchidism, micropenis, posterior urethral valves, and hypospadias are recognized in DS, its association with ambiguous genitalia has been reported rarely. Isolated cryptorchidism has been reported to occur in 14–27% of males with DS [1]. Lang *et al.* found that 9.89% of patients with DS had distal hypospadias [2].

We report a 1-year-old child reared as a male presenting with micropenis, penoscrotal hypospadias, and incompletely fused labial-scrotal folds with palpable gonads whose karyotype was 47, XY, +21. Genitourinary abnormalities in DS are often underreported, and minor signs of undervirilization such as isolated hypospadias, mild clitoromegaly/micropenis, and cryptorchidism may suggest an androgen biosynthetic defect or insensitivity. This case report is the first of its kind reported from India.

CASE REPORT

A 1-year-old baby assigned male sex at birth was the first child born of a non-consanguineous marriage by full-term vaginal delivery with birth weight of 2.2 kg. The mother's age at conception was 19 years. There was no antenatal history of gestational diabetes, thyroid disorders, fever, or exposure to drugs. The newborn was noticed to have dysmorphic facies and ambiguous genitalia. There was no history suggestive of salt wasting or hyperpigmentation. The baby had neonatal jaundice requiring phototherapy and was

exclusively breastfed for 6 months. The baby on presentation could speak monosyllables, sit without support, and stand with support.

On examination, pulse rate was 110/min and systolic BP was 80/50 mmHg (between 50 and 90 centiles) and other vitals were within normal limits. Height and weight were around the 10th centile. The patient had clinical features suggestive of DS which included a depressed nasal bridge, low set ears, protruding tongue, flat head, short hands and neck, epicanthic fold, flat nose, separated 1st and 2nd toe, short 4th metatarsal, simian crease, and sparse hair (Fig. 1). Penile length was 1.5 cm with penoscrotal hypospadias and incompletely fused labioscrotal folds with palpable gonads of 1 ml in volume and firm consistency (Fig. 2). The external masculinization score was 3/12. There was no hyperpigmentation or goiter.

On investigation, the serum sodium and potassium were 139 mmol/l and 4.9 mmol/l, respectively. Hormonal evaluation revealed follicle-stimulating hormone - 9.47 mIU/ml, luteinizing hormone - 4.19 mIU/ml, 17 OHP - 0.70 ng/ml, and 8 am cortisol - 18.13 mcg/dl. A 20-cell karyotype was 47, XY, +21 (Fig. 3). The values of thyroid functions were thyroid-stimulating hormone - 2.68 mIU/ml and free thyroxine hormone - 0.72 ng/dl with antithyroid peroxidase antibody - 630 IU/ml ($n < 40$ IU/ml). The basal and post-human chorionic gonadotropin (HCG)-stimulated reports are mentioned in Table 1. An ultrasound of the inguinoscrotal region found testes in the scrotal region (right testis 12 mm × 5 mm and left testis 11 mm × 5 mm) with a patent processus vaginalis sac containing fluid in the left side. Mullerian

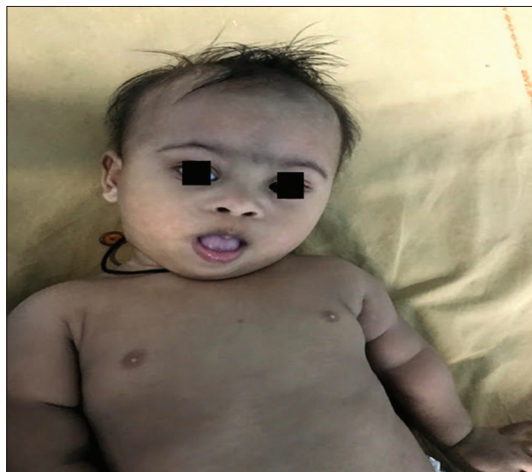

Figure 1: Clinical features suggestive of Down syndrome which included a depressed nasal bridge with flat nose, low set ears, protruding tongue, and epicanthic folds

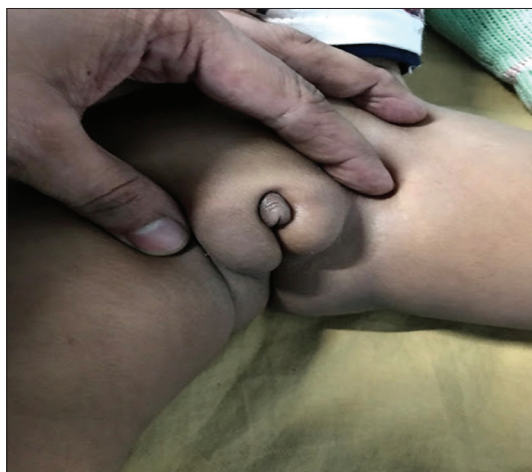

Figure 2: Micropenis, penoscrotal hypospadias, and incompletely fused labial-scrotal folds with palpable gonads

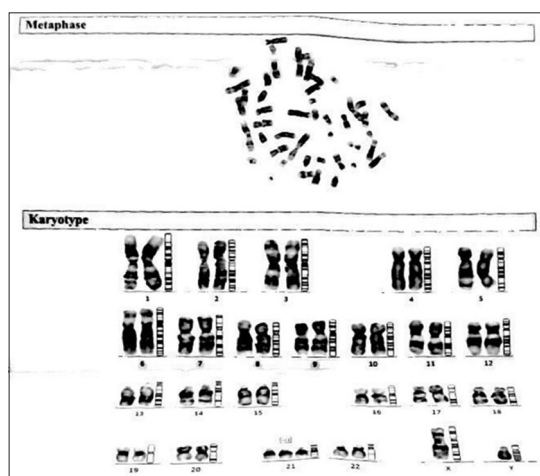


Figure 3: Karyotype 47, XY, +21

structures were absent. A 2D echocardiogram was normal. A follow-up of the patient was scheduled after 6 months. Hence, the patient has not been followed-up yet.

Table 1: HCG-stimulated reports of the patient

Investigations	Basal	Stimulated	Reference range
Testosterone (ng/ml)	0.21	0.95	<4.0
Androstenedione (ng/ml)	<0.30	1.02	0.4–2.6
DHT (pg/ml)	85	808.62	<30
T/A	0.7	0.9	>0.8
T/DHT	2.47	1.17	<10

HCG: Human chorionic gonadotropin, DHT: Dihydrotestosterone

DISCUSSION

DS continues to be the most common chromosomal disorder affecting 1 in 1150 live-born babies in India [3,4]. It usually arises due to trisomy 21 secondary to non-disjunction during gametogenesis in 95% cases, or it can be due to Robertsonian translocation and mosaicism which accounts for 3–2%, respectively [5].

Although urogenital malformations such as hypospadias and cryptorchidism are commonly reported in DS, its association with ambiguous genitalia is rarely seen. The first reported case was a newborn girl with congenital adrenal hyperplasia (CAH) whose karyotype showed translocation [6]. Golbus *et al.*, in 1973, reported a child with 47, XY, +21 with bilateral inguinal testes, ambiguous genitalia, and no apparent internal female genitalia, suggesting androgen insensitivity which could not be confirmed since testosterone values were not measured [7]. Dykes *et al.*, in 1984, also reported a similar case possibly due to 17–20 lyase enzyme defect [8]. Mello *et al.*, in 1974, reported a child with mosaic karyotype 47, XY, +21/46, XO, +21 in whom bifid scrotum with a palpable gonad on the left side, and penoscrotal hypospadias with a urogenital sinus were present [9].

Since the patient was normotensive without electrolyte disturbance or hypoadrenalism, androgen biosynthetic defects such as CAH, P450 oxidoreductase deficiency, 3-beta-hydroxysteroid dehydrogenase deficiency and 17 α hydroxylase/17, 20-lyase deficiency can be ruled out. Post-HCG-stimulated ratios were not suggestive of 17 beta-hydroxysteroid dehydrogenase deficiency or 5 α reductase Type 2 deficiency, and hence, a diagnosis of partial androgen insensitivity was made. Viner *et al.*, in 1996, reported three cases of DS with features of androgen insensitivity. All the three patients had a karyotype of 47, XY, +21 and reared as females. One individual had a normal female phenotype, and two showed minimal clitoromegaly and labial fusion [10]. Our child was reared as male and had micropenis with penoscrotal hypospadias, incompletely fused labioscrotal folds with palpable gonads.

The association of genital ambiguity with DS may suggest the possibility for an unrecognized gene in chromosome 21 which may be involved in the sex differentiation pathway. Genital abnormalities in DS such as isolated hypospadias, micropenis, or mild clitoromegaly are frequently underreported, and there is a possibility that some of these may be due to androgen insensitivity. These minor signs of undervirilization may support the hypothesis that genes in chromosome 21 may

have a role in the sex differentiation and androgen response. Foster JW *et al.*, 1994, suggested that the sex-determining region Y (SRY)-related high-mobility group (HMG) box (SOX) gene which is closely related to the SRY gene responsible for testes development in humans may be present on chromosome 21 [11]. The features of undervirilization may be due to the allelic heterogeneity in dosage-sensitive SOX-related gene on trisomic chromosomes [12,13].

We could not carry out genetic testing due to lack of its availability at our hospital and financial constraints of the family. We believe that further research is needed to determine the role of chromosome 21 in sex determination and androgen response.

CONCLUSION

This is the first reported case of DS associated with ambiguous genitalia in India. A strong index of suspicion for androgen insensitivity should be considered in case of minor signs of undervirilization such as isolated hypospadias or cryptorchidism.

REFERENCES

1. Wilson GN, Wilson G, Cooley WC. Preventive Management of Children with Congenital Anomalies and Syndromes. Cambridge: Cambridge University Press; 2000. p. 580.
2. Lang DJ, Van Dyke DC, Heide F, Lowe PL. Hypospadias and urethral abnormalities in down syndrome. *Clin Pediatr (Phila)* 1987;26:40-2.
3. CDC. Data and Statistics. Down Syndrome. Birth Defects. NCBDDD. CDC. Centres for Disease Control and Prevention; 2017. Available from: <https://www.cdc.gov/ncbddd/birthdefects/downsyndrome/data.html>. [Last cited on 2018 Sep 10].

4. Verma IC. Burden of genetic disorders in India. *Indian J Pediatr* 2000;67:893-8.
5. Shin M, Siffel C, Correa A. Survival of children with mosaic down syndrome. *Am J Med Genet A* 2010;152A:800-1.
6. Srivathana S, Collipp PJ, Sherman J, Zaino E. Translocation mongolism with virilizing adrenal hyperplasia. *Am J Clin Pathol* 1971;55:232-6.
7. Golbus MS, Beauchamp CJ, Conte FA. Male pseudohermaphroditism in a child with down's syndrome. *J Med Genet* 1973;10:189-92.
8. Dykes L, Fragoso MA, Helfer RE, Kapur S, Netzloff ML. Ambiguous genitalia in a newborn male with down syndrome. *Pediatr Res* 1984;18:307A.
9. Mello RS, Souza OA, Mello EM, Pimentel EC. Patient with down's syndrome and male pseudohermaphroditism with a 47, XY, +21/46, X, +21 karyotype. *Clin Genet* 1974;5:259-62.
10. Viner RM, Shimura N, Brown BD, Green AJ, Hughes IA. Down syndrome in association with features of the androgen insensitivity syndrome. *J Med Genet* 1996;33:574-7.
11. Foster JW, Dominguez-Steglich MA, Guioli S, Kwok C, Weller PA, Stevanović M, *et al.* Campomelic dysplasia and autosomal sex reversal caused by mutations in an SRY-related gene. *Nature* 1994;372:525-30.
12. Goodfellow PN, Lovell-Badge R. SRY and sex determination in mammals. *Annu Rev Genet* 1993;27:71-92.
13. Ogata T, Hawkins JR, Taylor A, Matsuo N, Hata J, Goodfellow PN, *et al.* Sex reversal in a child with a 46, X, Yp+ karyotype: Support for the existence of a gene(s), located in distal xp, involved in testis formation. *J Med Genet* 1992;29:226-30.

Funding: None; Conflict of Interest: None Stated.

How to cite this article: Valsaraj R, Goswami S, Ray A, Sengupta N, Sahana PK, Baidya A. Down syndrome with ambiguous genitalia: A rare association. *Indian J Case Reports*. 2018; November 29 [Epub ahead of print].