

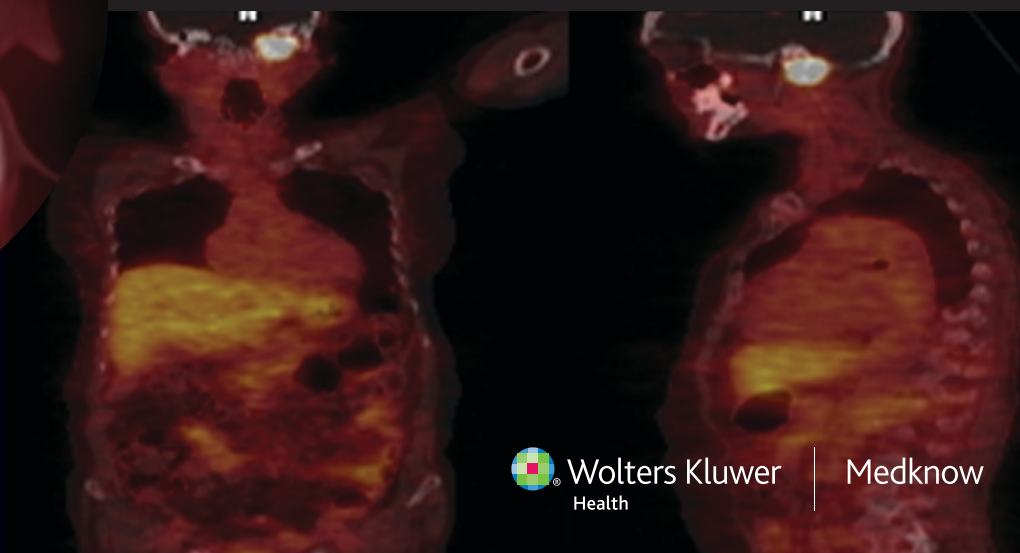
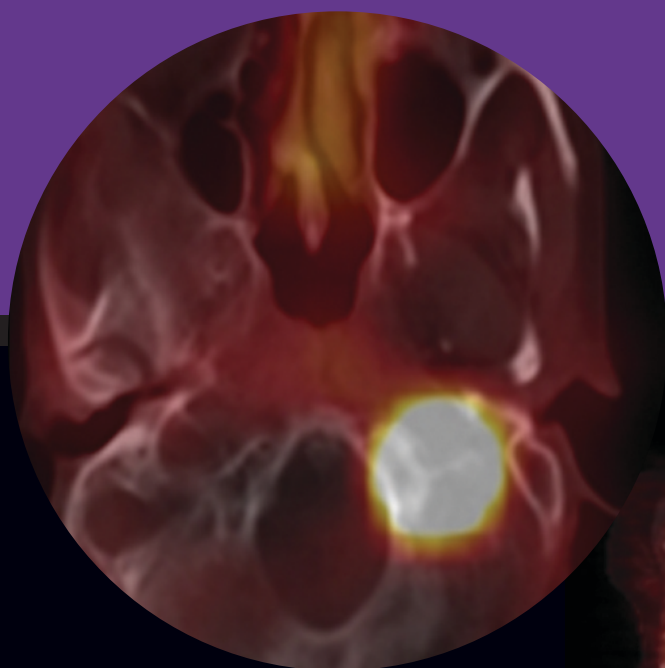


November-December 2012 / Vol 16 / Issue 6

Indian Journal of Endocrinology and Metabolism

Official Publication of The Endocrine Society of India

www.ijem.in



Rare presentation of a common disease: Idiopathic hypoparathyroidism presenting with extrapyramidal symptoms and status epilepticus

Kaushik Ghosh, Nilanjan Sengupta¹, Tanmoy Jyoti Sau, Atri Chatterjee

Departments of Medicine, and ¹Endocrinology, NRS Medical College, Kolkata, India

ABSTRACT

We report of an 18-year-old male who presented with an epileptiform disorder, features of hypocalcemia, and an extrapyramidal symptom in the form of choreoathetosis. On evaluation he had idiopathic hypoparathyroidism with extensive calcifications in the extrapyramidal system of the brain; basal ganglion, as well as in the cerebral cortex and cerebellum, which is a rare entity. We report the rare presentation of a common disorder, which requires to be considered in evaluating hypoparathyroidism.

Key words: Extrapyramidal symptoms, hypoparathyroidism, status epilepticus

INTRODUCTION

Hypoparathyroidism can occur as a result of congenital development disorder, iatrogenic causes (e.g., drugs, parathyroid gland removal during thyroid surgery, radiation), suppression of parathyroid function, such as in hypomagnesaemia, infiltrative diseases (malignancy, sarcoidosis, Wilson's disease) or as an idiopathic variety. The idiopathic variety is diagnosed when all secondary causes are excluded clinically or by investigations. Basal ganglia calcification is well known in hypoparathyroidism, but extensive intracranial calcification beyond the extrapyramidal system is rare.^[1,2] Most of the basal ganglia calcifications are asymptomatic. Here we present a case of idiopathic hypoparathyroidism presenting with extensive intracranial calcification, with features of extrapyramidal system involvement, along with status epilepticus.

CASE REPORT

An 18-year-old male patient presented to the emergency room of our hospital with new onset of generalized tonic–clonic seizure. He had no evidence of cognitive impairment, or any dysmorphic body feature. On examination, he had Chvostek's and Trousseau's signs. He demonstrated regular, slow, jerky movements of the right hand, resembling choreoathetosis. There were no cerebellar signs or any heterotrophic calcium deposition on the skin or elsewhere. Fundoscopy was normal. The remainder of the examination was unremarkable. His baseline evaluation revealed sodium of 137 meq / L, potassium of 3.6 meq / L, bicarbonate of 23 meq / L, magnesium of 1.4 mg / dL (normal 1.8 to 2.4 mg / dl), corrected calcium of 3 mg / dl (normal 8.8 to 10.6 mg / dl), phosphorus of 6.5 mg / dl (normal 2.5 to 4.9 mg / dl), albumin of 4 g / dl, urea of 25 mg / dl, and creatinine of 0.9 mg / dl.

Intact parathormone in the serum was 2.77 pg / ml (normal 15 to 65 pg / ml) and 1,25 dihydroxy vitamin D3 was 11.9 pg / ml (normal 19.6 to 54.3 pg / ml). Computed tomography of the brain showed bilateral extensive calcification involving the thalamus, dentate nuclei, putamen, globus pallidus, caudate nucleus, subcortical white matter and cerebellum [Figure 1]. Ultrasonography

Access this article online

Quick Response Code:



Website:
www.ijem.in

DOI:
10.4103/2230-8210.103035

Corresponding Author: Dr. Kaushik Ghosh, Department of Medicine, NRS Medical College, 138 AJC Bose Road, Kolkata – 700 014, India.
E-mail: drkaushikghosh@gmail.com

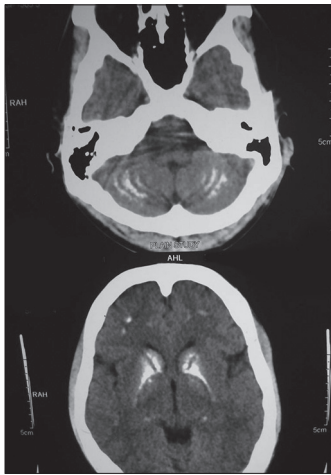


Figure 1: Computed tomography of the brain showed bilateral extensive calcification involving the thalamus dentate nuclei, putamen globus pallidus, caudate nucleus, subcortical white matter, as well as the cerebellum

of abdomen was normal with regard to kidney size and corticomedullary differentiation. With these investigations, after ruling out other causes of hypoparathyroidism, the diagnosis of idiopathic hypoparathyroidism was made and patient was treated with IV and oral calcium preparations, along with Vitamin D3 and haloperidol. In the course of hospital stay, his symptoms improved, he had no further seizures, and had normal calcium, magnesium, and phosphate. However, the choreoathetoid movement of the hand responded poorly.

DISCUSSION

Hypoparathyroidism is an endocrine disorder that can be a result of diverse reasons. When no obvious cause is detected it is termed as the idiopathic variety.^[3] Clinical manifestations in hypoparathyroidism result from hypocalcemia, while biochemical abnormalities reveal hyperphosphatemia, in addition to decreased detectable levels of serum parathyroid hormone and calcium.^[4] Radiologically hypoparathyroidism causes calcification, often only in bilateral basal ganglia,^[5] of which the most common site is globus pallidus. Beyond the basal ganglia, asymptomatic calcification is very rare. Despite the extensive involvement of the extrapyramidal system, symptoms attributable to their involvement are uncommon at the clinical presentation.^[1] Of three earlier cases reported by Mandelson *et al.*^[1] only one had true idiopathic hypoparathyroidism. Goel *et al.*^[6] reported another case of idiopathic hypoparathyroidism, where

the intracerebral calcification was beyond the basal ganglia, involving the cerebellum and cortex. The present case also had extensive intracranial calcification involving the basal ganglia, cerebellum, and entire cortex.

Physiological intracranial calcification occurs in about 0.3–1.5% of the cases, and is asymptomatic and incidentally detected by computed tomography. Among various causes of pathological basal ganglia calcification, apart from hypoparathyroidism and pseudohypoparathyroidism metabolic disorders, infectious and genetic diseases are common. Besides tetany and seizure, intracranial calcifications can present with Parkinsonism and dementia. Infections (toxoplasmosis, rubella, cytomegalovirus, cysticercosis, AIDS) can present with multiple and asymmetric intracranial calcifications, whereas, inherited and neurodegenerative diseases cause symmetrical, bilateral basal ganglia calcification.

We report this rare presentation of idiopathic hypoparathyroidism with extensive intracranial calcifications beyond the extrapyramidal system, presenting with extrapyramidal symptoms and status epilepticus.

REFERENCES

1. Mendelsohn DB, Hertzanu Y, Friedman L. Hypoparathyroidism with cerebral calcification extending beyond extrapyramidal system. *S Afr Med J* 1984;65:781-2.
2. McLeod DR, Hanley DA, McArthur RG. Autosomal dominant hypoparathyroidism with intracranial calcification outside the basal ganglia. *Am J Med Genet* 1989;32:32-5.
3. Girija AS. Idiopathic hypoparathyroidism with extensive intracranial calcification associated with kinesogenic choreoathetosis. *J Assoc Physicians India* 2000;48:938-9.
4. Vogler JB, Kim JH. Metabolic and endocrine diseases of the skeleton. In: Grainger RG, Allison D, Adam A, Dixon AK, editors. *Diagnostic radiology. A textbook of medical imaging*. 4th ed. London, England: Churchill Livingstone; 2001. p. 1925-65.
5. Fulop M, Zeifer B. Case report: Extensive brain calcification in hypoparathyroidism. *Am J Med Sci* 1991;302:292-5.
6. Goel A, Bhatnagar MK, Vashishta A, Verma NP. Hypoparathyroidism with extensive intracranial calcification: A case report. *Postgrad Med J* 1994;7:913-5.

Cite this article as: Ghosh K, Sengupta N, Sau TJ, Chatterjee A. Rare presentation of a common disease: Idiopathic hypoparathyroidism presenting with extrapyramidal symptoms and status epilepticus. *Indian J Endocr Metab* 2012;16:1035-6.

Source of Support: Nil, **Conflict of Interest:** No.